

## Effect of Orthodontic Loading on Periodontal Ligament Proliferation: A Preliminary Study

Issarintip Denkongpon<sup>1</sup>, Boonsiva Suzuki<sup>1</sup>, Eduardo Yugo Suzuki<sup>1</sup>

<sup>1</sup>Department of Orthodontics, Faculty of Dentistry, Bangkokthonburi University, Bangkok, Thailand

### Abstract

The preapplication of orthodontic loading enhances the proliferation of the periodontal ligament (PDL) and is beneficial for tooth autotransplantation (TAT). However, the changes in the PDL thickness following loading application are unknown. The purpose of the present study was to determine the changes of remaining periodontal ligament (PDL) thickness on the root surface of extracted premolars following orthodontic loading. Twenty-four premolars were divided into control and preloaded (4, 8, and >12-weeks) groups. Premolars were extracted, fixed, and stained with toluidine blue for the assessment of the remaining PDL. The radicular portion was sectioned into apical, middle, and coronal thirds. Images of the sections were recorded under a stereomicroscope and the PDL thickness was measured with ImageJ software. Data was collected and analyzed statistically. The preloading groups (4, 8, and >12-weeks) showed a significant increase in the overall PDL thickness compared to the control ( $0.123 \pm 0.01$  mm) ( $P < 0.01$ ). The 8-weeks group ( $0.198 \pm 0.022$  mm) provided the highest increase in overall PDL thickness among the preloading groups ( $P < 0.05$ ). No statistical difference in the PDL thickness between the 4-weeks ( $0.153 \pm 0.014$  mm), >12-weeks ( $0.157 \pm 0.019$  mm) groups was observed. The 8-weeks orthodontic preloading duration provided the highest increase in the PDL thickness. After this period, the PDL thickness rebounded, therefore indicating the rebound of the PDL. An increase in PDL thickness is advantageous for the success of TAT.

**Keywords:** Orthodontic loading, PDL thickness, Tooth autotransplantation

**Received Date:** Jul 19, 2021    **Revised Date:** Aug 7, 2021    **Accepted Date:** Sep 9, 2021

**doi:** 10.14456/jdat.2021.40

#### Correspondence to:

Eduardo Yugo Suzuki, Department of Orthodontics, Faculty of Dentistry, Bangkokthonburi University 16/10 Leabklongtaweewatana Rd., Taweewatana District, Bangkok 10170, Tel: +66-53-274420 Email: yugotmdu@hotmail.com, eduardo.suz.@bkkthon.ac.th

### Introduction

Tooth autotransplantation (TAT) has been an alternative approach in orthodontic practice to replace missing or hopeless teeth.<sup>1</sup> Various treatment protocols for autogenous tooth autotransplantation have been described

and high success rates were reported.<sup>2</sup> Successful periodontal ligament (PDL) healing after tooth replantation can be expected if damage to the PDL of the donor's tooth during extraction is reduced and limited.<sup>1,3</sup> The prognosis of TAT

has been greatly improved by preserving the supporting tissues using careful surgical strategies to preserve the PDL around the extracted root surface.

The PDL is a soft cellular connective tissue richly vascularized surrounding the root of the teeth and joining the root cementum with alveolar bone.<sup>4</sup> The periodontal ligament is responsible for orthodontic tooth movement and transmits orthodontic appliance force to the alveolar bone. When the orthodontic loading is applied to a tooth, a proliferation of the PDL occurs followed by bone remodeling and tooth migration.<sup>5</sup> The proliferation of the PDL combined with bone remodeling results in a radiographic finding characterized by the radiolucent space between the lamina dura and the tooth root, or the widening of the PDL space.<sup>6</sup> The widening of the PDL causes changes in the biomechanical characteristics of the periodontium and an increase in tooth mobility.<sup>7</sup> Therefore, the widening of the PDL plays an important role in the physiological aspect of tooth movement.<sup>5</sup>

The presence of intact and viable PDL cells on the root surface of the donor's tooth decreases complications after transplantation including ankylosis. Clinical and experimental studies have suggested that the preapplication of mechanical stimuli to the donor's teeth increases the PDL and eases the extraction.<sup>1,4,8</sup> In a study with animals, preloading of light orthodontic force for seven days before extraction significantly increased the PDL space as well as the width of the alveolar socket, resulting in rich PDL tissues attached to the root surface of the extracted teeth.<sup>1</sup>

In a study with humans, Nakdilok *et al.*,<sup>8</sup> found that the optimal duration for stimulating the PDL proliferation and ease of extraction was 4 weeks of orthodontic preloading force. However, the assessment of the PDL enhancement was performed two-dimensionally based on the percentage of stained PDL on the root surface. Moreover, no information regarding the thickness of the remaining PDL on the root surface of an extracted tooth was provided.

A classic article from Coolidge in 1937<sup>9</sup> measured the PDL space in humans. Specimens were obtained from cadavers and histologic sections of the PDL space at the alveolar crest, middle and apical sites were used

for measurements. The average normal width of the PDL space ranged from 0.15 mm to 0.21 mm, which decreased with age and function. The thinnest width of the PDL was located at the middle portion.

Recently, measurement of the PDL space width was performed using imaging obtained from the CBCT images of dry human mandibular bone. The PDL space widths ranged from 0.16 mm and 0.28 mm.<sup>10</sup> The authors concluded that the CBCT images obtained at 0.075 mm voxel size are preferred for the accurate measurement of PDL space.

Although the preapplication of orthodontic loading enhances the proliferation of the PDL and facilitates the simple extraction of the donor's tooth, no information regarding the thickness of the remaining PDL on the root surface of an orthodontically preloaded donor tooth, as well as the optimum loading duration was available.

Therefore, the purpose of the present study was to determine the changes of the remaining PDL thickness on the root surface of extracted premolars following orthodontic preloading and to define the optimum preloading period.

## Materials and Methods

### Participants

In the present study, twenty-four premolars of six patients (age  $21.5 \pm 4$  years), at the Graduate Clinic, Department of Orthodontics, Faculty of Dentistry, Bangkokthonburi University were used. Premolars were referred for removal as part of the orthodontic treatment planning from January to September 2019. To be included in the study sample, patients had to be healthy and free of periodontitis. The patients were excluded as study participants if they had any missing data or recall visits or they reported the use of nontrivial drugs during the observation period.

The study was conducted in agreement with the Helsinki Declaration and ethical approval was obtained from the Bangkokthonburi University Research Ethics Committee (No. 3/2564). Detailed procedures and potential

risks were explained to each patient, who provided written and dated informed consent before the study.

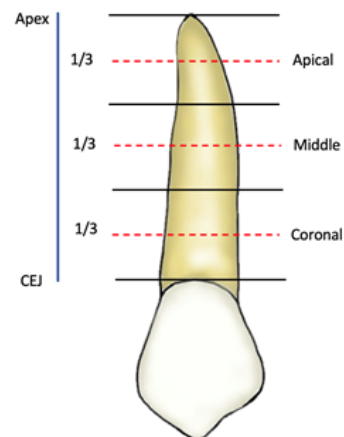
### Orthodontic Preloading

In the present study, each patient had their premolar orthodontics loaded for 4, 8, and >12 weeks before the extraction. A contralateral premolar that was not loaded served as a control. The orthodontic preloading was performed using a 0.016-inch improved superelastic nickel-titanium alloy wire (Sentalloy<sup>®</sup>, Tomy International, Inc., Tokyo, Japan) that was engaged to the fixed appliances. The orthodontic loading was provided by the Sentalloy archwire that was connected to the brackets on the buccal surface of the premolars, thus generating buccal-lingual force vectors. The 0.016" Sentalloy archwire generates light and continuous force (100 g).<sup>8</sup>

### Toluidine Blue Staining

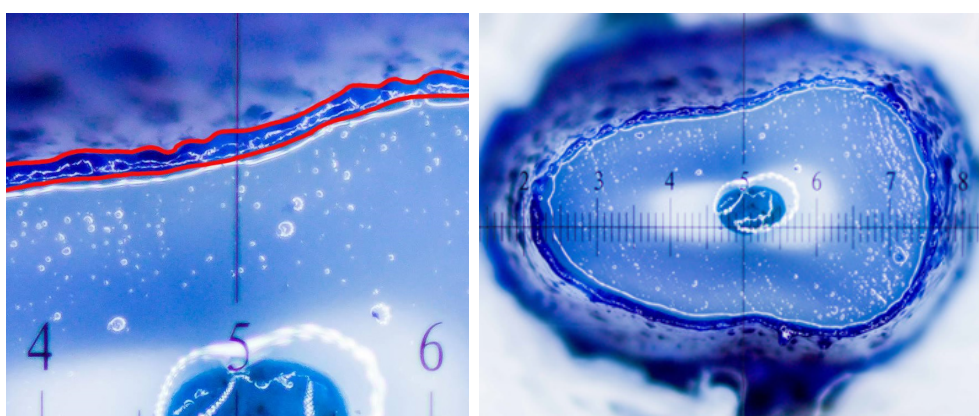
Staining with toluidine blue was performed to determine the amount of PDL tissue with proliferative cells on the root surface. The extracted teeth were washed gently in phosphate-buffered saline (PBS), pH7.4, and fixed with 10% buffered formalin solution in 50-ml tubes (Corning, Inc., Corning, NY, USA) for 24 h. The teeth were stained with 0.04% (w/v) toluidine blue (Sigma-Aldrich, St. Louis, MO, USA) for one min, and de-stained with 4 ml of PBS, which was changed daily for two days. After destaining, the teeth were photo recorded and sectioned.

### Measurement of the Stained PDL Area on the Root Surface



**Figure 1** The radicular portion was divided equally according to its length into apical, middle, and coronal thirds

After staining, the radicular portion was sectioned by thirds into the apical, middle, and coronal using a diamond disk. (Fig 1.) Each sample was sectioned perpendicular to the tooth's long axis and then digitally photographed under a stereomicroscope (Earkin FHD3860 (0.7-4.5x); Shenzhen Juaiqu Electronic Co., Ltd., Shenzhen, China). Images were analyzed using ImageJ software version 1.51r (National Institute of Health, Bethesda, MD, USA), and the stained area indicating the PDL thickness was measured. (Fig 2.) Each section was subdivided into; buccal, lingual, mesial and distal surfaces. Each surface was equally subdivided into 10 sites. The measurements of PDL thickness were performed in these 10 sites and averaged.



**Figure 2** A. The 4.0 x magnifying image of the PDL thickness. B. The apical section of a preloaded tooth.

### Statistical analysis

Data were analyzed using SPSS statistical software (version 19.0; SPSS Inc, Chicago, Ill). The data normal distribution was confirmed by the Shapiro-Wilk test. Differences in the PDL thickness between the control and the preloading were assessed by two-way repeated measures ANOVA. Comparison of PDL thickness within groups was performed with one-way ANOVA followed by multiple comparisons using the Bonferroni and the Dunnett T3 test. The results were considered statistically significant for  $P < 0.05$ .

## Results

The preloading groups (4, 8, and >12-weeks) showed a significant increase in the overall PDL thickness compared to the control ( $0.123 \pm 0.01$  mm) ( $P < 0.01$ ). The 8-weeks group ( $0.198 \pm 0.022$  mm) provided the highest increase in overall PDL thickness among the preloading groups ( $P < 0.05$ ). No statistical difference in the PDL thickness between the 4-weeks group ( $0.153 \pm 0.014$  mm), and the >12-weeks group ( $0.157 \pm 0.019$  mm) was observed. (Fig 3.)

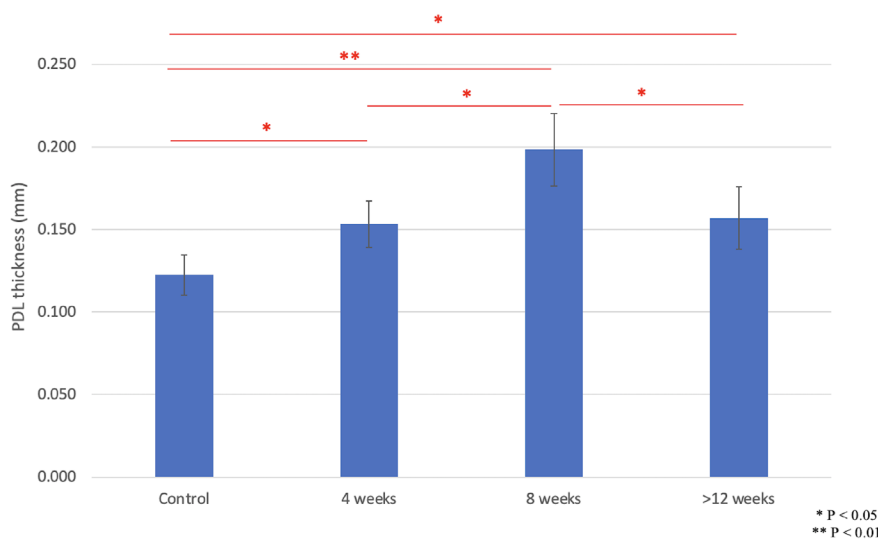


Figure 3 Changes in the PDL thickness following orthodontic preloading

## Discussion

The preapplication of orthodontic loading on the donor's tooth increases the proliferative and metabolic activities of the PDL cells and eases the extraction, thus reducing the risks of PDL tissue damage.<sup>1,4,8</sup> Consequently, common complications such as root resorption and ankylosis following the TAT can be reduced.<sup>2,3</sup>

In the present study, the assessment of remaining PDL thickness on the root surface of extracted premolars following orthodontic preloading was performed to define the optimum preloading period.

The results have confirmed the overall increase in PDL thickness in the preloading groups (4, 8, and >12 weeks) compared to the control group. This is the result

of the orthodontic loading on the PDL which causes the bone resorption through the osteoclastic activity, thus creating irregular cavities in the bone with the simultaneous increase in the PDL thickness.<sup>11</sup> The results are in agreement with previous studies that investigate the effects of orthodontic loading on PDL proliferation.<sup>1,8,12</sup> Suzaki *et al.*,<sup>1</sup> in a histomorphological study had reported the increase in the PDL thickness following the application of orthodontic loading in rats. Nakdilok *et al.*,<sup>8</sup> concluded that a 4-weeks period was sufficient to provide a significant increase of the overall percentage of stained PDL on the surface of the root of the preloaded tooth.<sup>8</sup> Promchaiwattana *et al.*,<sup>13</sup> confirmed the PDL enhancement following the application of Smart

Springs for the orthodontic extraction of mesio-angulated mandibular third molars. However, in these studies, only a two-dimensional topographic analysis of the root surface with no information regarding the PDL thickness was performed. Therefore, the results of the present study provide complementary insight into the PDL proliferative characteristics.

In the present study, the 8-weeks group exhibited the highest amounts of increased PDL thickness among the preloading groups. This is a new finding of the study since most of the studies that investigated PDL proliferation reported four weeks for the maximum expression of the PDL enhancement.<sup>12</sup> Therefore, the presented results are not in agreement with the study of Phutinart *et al.*,<sup>12</sup> who evaluated the expressions of bone biomolecules in the increased PDL volumes. In their study, the authors had concluded that orthodontic preloading for four weeks enhances the amounts of PDL tissue together with the RUNX2 and ALP expressions and the RANKL/OPG ratio in the PDL, suggesting that this loading period is suitable for successful TAT. However, the observation period used by these authors was limited to four weeks. Consequently, the following PDL proliferation analysis was not performed. The findings of the present study suggest that the maximum expression of the biomolecules in the increased PDL volumes occurs within four weeks, while the maximum PDL thickness occurs in eight weeks. Therefore, further studies to assess the effects of the biomolecules and the PDL proliferation in three dimensions should be performed in future studies.

Results of the present study indicated that after the highest increase of PDL thickness at eight weeks, a significant decrease in the PDL thickness was observed in the >12-weeks periods. Whereas, no statistical difference in the PDL thickness between the 4 and >12-weeks groups was observed. The increase and decrease in the PDL thickness are interpreted as the rebound of PDL. The rebound of the PDL is the direct effect of its elastic characteristics combined with the continuous and progressive alveolar bone remodeling in an attempt

to achieve homeostasis.<sup>11</sup> The results are in agreement with previous studies that investigated the effect of orthodontic loading on periodontium.<sup>11,13</sup>

The effect of the orthodontic loading on the PDL resulted in the initial bone resorption combined with a simultaneous increase in PDL thickness that was measured in the 4-weeks group.<sup>13</sup> The maximum expression of the PDL thickness was achieved in the 8-weeks period. Following this period, the surrounding alveolar bone was filled by newly formed bone owing to osteoblast activity resulting in the rebound of the PDL. Consequently, the PDL thickness was significantly reduced in the >12-weeks groups.

To the author's knowledge, the assessment of the increase and rebound of the PDL thickness as a result of orthodontic loading has never been investigated. Consequently, the results obtained in the present study can be considered a new finding and deserves further investigation.

Although the PDL thickness varies along the root surface with the thinnest PDL in the middle portion, comparison of PDL thickness between apical, middle and coronal sections were not performed due to the reduced sample number. This is the main limitation of the present study. Therefore, further studies with an increased number of samples must be performed.

A limitation of the present study was the reduced number of participants and the possibility of intraindividual variation. Therefore, further studies with an increased number of samples must be performed.

The present study has demonstrated that a period of 8-week duration of orthodontic preloading is sufficient to adequately enhance the PDL and atraumatic extraction of the donor's tooth; both outcomes are beneficial for successful TAT.<sup>14</sup>

## Conclusion

The 8-weeks orthodontic preloading duration provided the highest increase in the PDL thickness. After this period, the PDL thickness rebounded, therefore indicating the rebound of the PDL.

## Acknowledgements

The authors acknowledge financial support from Bangkokthonburi University.

## References

1. Suzuki Y, Matsumoto Y, Kanno Z, Soma K. Preapplication of Orthodontic Forces to the Donor Teeth Affects Periodontal Healing of Transplanted Teeth. *Angle Orthod* 2008;78:495-501.
2. Andreasen JO, Paulsen HU, Yu Z, Bayer T, Schwartz O. A long-term study of 370 autotransplanted premolars. Part II. Tooth survival and pulp healing subsequent to transplantation. *Eur J Orthod* 1990;12(1):14-24.
3. Andreasen JO. Interrelation between alveolar bone and periodontal ligament repair after replantation of mature permanent incisors in monkeys. *J Periodontal Res* 1981;16(2):228-35.
4. Cho JH, Hwang HS, Chang HS, Hwang YC. Application of orthodontic forces prior to autotransplantation-case reports. *Int Endod J* 2013;46(2):187-94.
5. Tanaka E, Ueki K, Kikuzaki M, Yamada E, Takeuchi M, Dalla-Bona D, et al. Longitudinal measurements of tooth mobility during orthodontic treatment using a periostat. *Angle Orthod* 2005;75(1):101-5.
6. Isola G, Matarese G, Cordasco G, Perillo L, Ramaglia L. Mechanobiology of the tooth movement during the orthodontic treatment: A literature review. *Minerva Stomatologica* 2016;65(5):299-327.
7. Tanne K, Inoue Y, Sakuda M. Biomechanical behavior of the periodontium before and after orthodontic tooth movement. *Angle Orthod* 1995;65(2):123-8.
8. Nakdilok K, Langsa-Ard S, Krisanaprakornkit S, Suzuki EY, Suzuki B. Enhancement of human periodontal ligament by preapplication of orthodontic loading. *Am J Orthod Dentofacial Orthop* 2020;157(2):186-93.
9. Coolidge ED. The Thickness of the Human Periodontal Membrane. *J Am Dent Assoc* 1937;24(8):1260-70.
10. Kucuk NO, Kamburoğlu K, Öztürk E, Küçük Ö. The accuracy of periapical radiography and cone beam computed tomography in measuring periodontal ligament space: Ex vivo comparative micro-CT study. *Aust Endod J* 2020;46(3):365-73.
11. Krishnan V, Davidovitch Z. Cellular, molecular, and tissue-level reactions to orthodontic force. *Am J Orthod Dentofacial Orthop* 2006;129(4):469.e1-32.
12. Phutinart S, Krisanaprakornkit S, Makeudom A, Suzuki B, Suzuki EY. Periodontal ligament proliferation and expressions of bone biomolecules upon orthodontic preloading: Clinical implications for tooth autotransplantation. *Korean J Orthod* 2020;50(3):188-96.
13. Promchaiwattana P, Suzuki B, Krisanaprakornkit S, Suzuki EY. Periodontal ligament enhancement in mesio-angulated impaction of third molars after orthodontic tooth movement: A prospective cohort study. *Am J Orthod Dentofacial Orthop* 2020;158(4):495-504.
14. Suzuki EY. Authors' response. *Am J Orthod Dentofacial Orthop* 2021;160(1):7-8.